

RESEARCH ARTICLE

Open Access

Cross-sectional imaging of the torso reveals occult injuries in asymptomatic blunt trauma patients



Gregory J. Roberts^{1*} , Lewis E. Jacobson¹, Michelle M. Amaral², Courtney D. Jensen², Louis Cooke¹, Jacqueline F. Schultz¹, Alexander J. Kinstedt¹ and Jonathan M. Saxe¹

Abstract

Background: High morbidity and mortality rates of trauma injuries make early detection and correct diagnosis crucial for increasing patient's survival and quality of life after an injury. Improvements in technology have facilitated the rapid detection of injuries, especially with the use of computed tomography (CT). However, the increased use of CT imaging is not universally advocated for. Some advocate for the use of selective CT imaging, especially in cases where the severity of the injury is low. The purpose of this study is to review the CT indications, findings, and complications in patients with low Injury Severity Scores (ISS) to determine the utility of torso CT in this patient cohort.

Methods: A retrospective review of non-intubated, adult blunt trauma patients with an initial GCS of 14 or 15 evaluated in an ACS verified level 1 trauma center from July 2012 to June 2015 was performed. Data was obtained from the hospital's trauma registry and chart review, with the following data included: age, sex, injury type, ISS, physical exam findings, all injuries recorded, injuries detected by torso CT, missed injuries, and complications. The statistical tests conducted in the analysis of the collected data were chi-squared, Fischer exact test, and ANOVA analysis.

Results: There were 2306 patients included in this study, with a mean ISS of 8. For patients with a normal chest exam that had a chest CT, 15% were found to have an occult chest injury. In patients with a negative chest exam and negative chest X-ray, 35% had occult injuries detected on chest CT. For patients with a negative abdominal exam and CT abdomen and pelvis, 16% were found to have an occult injury on CT. Lastly, 25% of patients with normal chest, abdomen, and pelvis exams with chest, abdomen, and pelvis CT scans demonstrated occult injuries. Asymptomatic patients with a negative CT had a length of stay 1 day less than patients without a corresponding CT. No incidents of contrast-induced complications were recorded.

Conclusions: A negative physical exam combined with a normal chest X-ray does not rule out the presence of occult injuries and the need for torso imaging. In blunt trauma patients with normal sensorium, physical exam and chest X-ray, the practice of obtaining cross-sectional imaging appears beneficial by increasing the accuracy of total injury burden and decreasing the length of stay.

Keywords: Blunt trauma, Computed tomography (CT), Occult injury, Asymptomatic

* Correspondence: Gregoryroberts215@gmail.com

¹Trauma Department, St. Vincent Indianapolis Hospital, 8240 Naab Road
#100, Indianapolis, IN 46260, USA

Full list of author information is available at the end of the article



Background

Trauma is the number one cause of death for people aged 1–44 and accounts for 19.2% of years of potential life lost in the United States. Additionally, the medical and loss-of-work cost from traumatic injuries totals well above \$500 billion annually in the United States [1]. Given the magnitude of this problem, it is imperative that practitioners intervene in both a life-saving and cost-effective manner.

There are multiple ways to evaluate and treat trauma patients. Advanced trauma life support (ATLS) directs a rapid assessment of the acutely injured patient using physical examination, plain radiographs, and ultrasound to increase survival [2]. The use of torso computed tomography (CT) comes with vague recommendations. The ATLS guidelines do not detail recommendations as to the appropriate use of CT, and it is unclear which patients require this scan. Despite this, torso CT use for trauma patients has become much more common.

As CT technology has improved, more injuries are detected in shorter periods of time [3, 4]. This has led some centers to use CT scanning of the torso liberally [5–9]. Whereas others advocate for use in selected patients [10, 11]. Advocates of selective CT for trauma argue that the benefits do not outweigh the complications, which include IV contrast issues, radiation exposure, and cost [12–14].

The use of either torso CT or a “pan CT,” which includes CT of the head, cervical spine, chest, abdomen, and pelvis, has been shown to be beneficial in severely injured patients that do not have a reliable physical exam [5, 15–17]. However, even in evaluable patients, the sensitivity of physical examination and plain radiographs remain dead-ended to detecting some injuries, and there is controversy with regard to selecting the appropriate patients to undergo torso CT [18–22].

The use of pan CT in trauma for stable, unevaluable adult trauma patients is popular. The role of pan CT in the awake, mildly injured, evaluable patient is less clear and still widely debated [17, 20, 22]. Similar statements are true for a torso or thoracoabdominal CT [23].

In our center, both the Emergency Department (ED) and trauma attending physicians are involved in the initial workup of trauma patients, depending on the level of activation. This has led to a wide practice variation in which patients receive a torso CT. It is up to the discretion of the ED physician based upon the physical examination whether the patient will receive a scan. The purpose of this study is to review the CT indications, findings, and complications in patients with low Injury Severity Score (ISS) to determine the utility of torso CT in this patient cohort.

Methods

A retrospective review of non-intubated, blunt trauma patients aged 15 years or older with an initial Glasgow Coma Scale (GCS) score of 14 or 15 evaluated in an American

College of Surgeons verified level 1 trauma center from July 2012 to June 2015 was performed. Data was obtained from the trauma registry and chart review and included: age, sex, injury type, mechanism, ISS, physical exam findings, all injuries recorded, injuries detected by torso CT, missed injuries, and complications. The Institutional Review Board at St. Vincent Hospital granted permission for this study.

Physical exam (PE) findings were captured from trauma or ED notes, and all patients were seen by the ED attending physician. All trauma consults and code 1 activations were seen by the attending trauma surgeon. Physical exam findings were regularly recorded on a template trauma history and physical (H&P) form and were ‘visible trauma (location),’ ‘chest wall (CW) tenderness to palpation,’ ‘CW crepitus,’ ‘CW ecchymosis,’ ‘abdominal (Abd) ecchymosis,’ ‘Abd distension,’ ‘Abd tenderness,’ ‘flank ecchymosis.’

Recorded laboratory values included hemoglobin, international normalized ratio (INR), pH, lactate, base deficit, blood alcohol level, urine drug screen. Initial chest X-ray (CXR) and pelvic X-ray, if performed, were recorded. Initial chest/abdomen/pelvis (C/A/P) CTs were recorded, as well as delayed C/A/P CTs. All injuries and incidental findings were recorded. Delayed CT was defined as imaging performed after the initial evaluation in the ED. Repeat CTs for other reasons (re-evaluation, operative planning) were not recorded as such. Statistical tests conducted in the analysis of the collected data were chi-squared, Fischer exact test, and ANOVA analysis.

Results

There were 2306 patients determined to be eligible for review from the registry. The mean ISS was 8, and the initial chest physical exam was normal in 1571 (68% of the patient population). The results are best broken up into three subgroups. Each of these subgroups has a negative physical exam in either the chest (C), abdomen and pelvis, (A/P), or chest, abdomen, and pelvis (C/A/P). In the first group, 829 (54%) of these patients received a chest CT, and 127 (15%) of these patients were found to have an occult chest injury. There were 1067 (56%) patients with a negative abdominal exam who had a A/P CT. From these patients, 174 (16%) were found to have an occult injury on CT. In the third grouping, 592 (43%) of the patients with normal C/A/P exams received a C/A/P CT. Of these patients, 150 (25%) demonstrated occult injuries by CT (Tables 1 and 2). In total, 434 patients with a negative CXR also received a chest CT. Out of this grouping, 151 (35%) had injuries detected on the chest CT. The three subgroups and CXR data can be seen in Fig. 1. Itemized injuries are detailed in Tables 3, 4, 5.

Asymptomatic patients with a negative CT of the chest and/or abdomen and pelvis had a mean length of stay (LOS) 1 day less than asymptomatic patients without a CT of the corresponding body region(s) ($p < 0.001$) (Table 6).

Table 1 Patient characteristics with and without chest symptoms

	Total sample	Asymptomatic chest	Symptomatic chest
N	2306	1571	735
Age (years)	52.07 ± 22.41	52.20 ± 22.83	51.81 ± 21.54
Male (%)	56	56	56
ISS	8.21 ± 6.31	7.51 ± 5.68	9.60 ± 7.25
Hospital LOS	4.02 ± 4.10	4.14 ± 4.33	3.72 ± 3.38
Mortality	0.43%	0.52%	0.28%

ISS Injury severity score, LOS Length of stay

There were 10 deaths (0.43%) in this cohort. There was no difference in mortality between asymptomatic chest with CT C and without CT C (4 (0.3%) vs 4 (0.3%), $p = 0.575$) or asymptomatic C/A/P with CT C/A/P or without (2 (0.1%) vs 4 (0.3%), $p = 0.481$). There was a statistical significance in mortality between those with asymptomatic abdominal exam with CT A/P and without (2 (0.1%) vs 7 (0.4%), $p = 0.043$) (Table 7). No incidents of contrast-induced complications were noted in the study period.

There were 2 asymptomatic patients that did not initially receive a CT, but later did. One revealed a hemothorax, 3 rib fractures, and a left diaphragmatic hernia. Another patient was found to have a grade 3 liver laceration. No other patients were recorded that presented with an asymptomatic body region exam without initial CT that was later found to have an occult injury on delayed CT. There were 10 delayed minor injuries recorded after radiologist overread.

Discussion

It is not surprising that overall mortality is low (0.43%) in this patient cohort given the low ISS. Even though we found a statistical significance in mortality between asymptomatic abdominal region with and without CT A/P, the numbers are low, and it is difficult to state that there is a real clinical benefit here.

We are not able to prove a benefit in morbidity for these patients based on the data. Only 2 patients that had no chest or abdominal findings on physical exam and did not have an initial torso CT were found to have injuries on a delayed torso CT. This is consistent with a Cochrane review by Van Vugt et al. published in 2013 comparing

selective torso CT versus routine torso CT—there just have not been enough quality trials to base a recommendation [18].

One year later, Caputo et al. published a systematic review and meta-analysis on whole-body CT versus selective CT in trauma patients that did show a significant mortality benefit for those that receive pan CT, even though their ISS was higher [24]. This study is different in the fact that Caputo looked at whole-body CT and the Cochrane review was specifically thoracoabdominal CT, as in our study.

Although they are not randomized controlled trials, there are several studies supporting pan CT in trauma. Salim et al. reported findings in a prospective observational study that changed management in 19% of stable trauma patients that received pan CT [8]. Yeguiayan et al. showed a 30-day reduction in mortality from 22% to 16% by using pan CT, and Self et al. showed that 26% of patients receiving CT C/A/P who were already receiving a head CT had unexpected findings that changed treatment [16, 25].

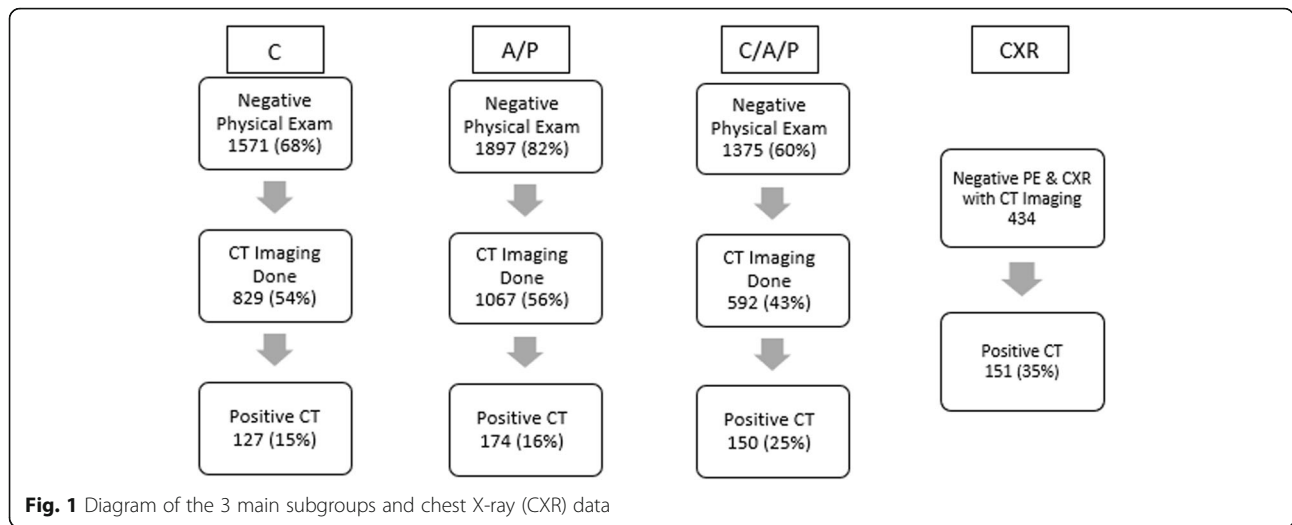
The first multicenter, randomized controlled trial (REACT-2) conducted by Sierink et al. compared immediate total-body CT with conventional imaging and selective CT. The authors concluded that immediate total-body CT was safer, quicker, and does not increase direct medical costs. However, they also found that this imaging does not change in-hospital mortality [26]. The median ISS (20) was significantly higher than in our cohort, so we do not have a direct comparison with that study group.

The study by Lee et al. comparing the cost-effectiveness of pan CT versus selective CT in stable, young adults resembles our cohort. The average ISS was 5 in this study, compared to 8 in ours and their population was much more uniform. They concluded that it is cost-effective to use pan CT based on mechanism alone, even in these mildly injured patients [20]. To relate cost-effectiveness to this study, the price for a CT A/P and the reading of it by a radiologist would be approximately \$1200 at our hospital, whereas a single day in the Trauma/Neurology Intensive care unit (TNICU) is approximately \$6500 and a day in the orthopedic unit is almost \$3000. This difference in price is significant and therefore it should be recognized that this reduction in LOS is cost-effective for the patient. It is noted that the cost of incidentalomas and contrast-induced complications were not included in that study [20]. However, one should consider the benefits of

Table 2 Occult injuries detected on CT by body region(s)

Asymptomatic body region	Number of patients	Corresponding CT	Number of positive CT
Chest	1571 (68%)	829 (54%)	127 (15%)
Abdomen	1903 (83%)	1067 (56%)	174 (16%)
C/A/P	1375 (60%)	592 (43%)	150 (25%)

C/A/P Chest/abdomen/pelvis, CT Computed tomography



serendipitous early detection of malignancy. We do not have data to show for this beyond personal experience and is perhaps a future area to study.

The risk of radiation exposure is always a concern with CT imaging. Sierink et al. published a study in 2013 showing an increase in initial radiation exposure after instituting a total-body CT protocol, but that total in-hospital radiation exposure was similar [27]. Another study also showed an increase in patients receiving more radiation (> 20 mSv) after instituting a trauma pan scan protocol [28]. The REACT-2 trial only showed a 0.3 mSv difference (i.e., 1 CXR) in radiation exposure of pan scan vs selectively scanned trauma patients. The exposure to radiation during a CT scan is easy to establish, but to say the risk of cancer conferred by that exposure is extrapolated and may

not be accurate; however, best estimates are about 29,000 cases of cancer are attributed to CT scans in the United States annually [29]. Tien et al. published a prospective cohort study of trauma patients’ average radiation exposure of 22.7 mSv level, which would be estimated to result in 190 cancer-related deaths per 100,000 patients exposed [30]. Though still greatly debated, it is our opinion that a single torso CT benefits outweigh this relatively small, theoretical risk in adults.

We show, in our retrospective study of mildly injured blunt trauma patients with a GCS of 14 or 15, that a surprising number of injuries are detected after normal chest and abdominal physical examinations, as well as chest X-ray. Four hundred sixty-eight injuries (or signs of suspected injuries requiring a change in management)

Table 3 Occult chest injuries

Normal chest PE with abnormal CT C	Number (%)
Bilateral rib fractures	5 (0.6)
Clavicle fracture	12 (1.5)
Lung contusion	17 (2.1)
Pneumothorax	25 (3.1)
1–2 rib fractures	38 (4.7)
3–6 rib fractures	25 (3.1)
> 6 rib fractures	7 (0.87)
Scapular fracture	14 (1.7)
Splenic injury	4 (0.50)
Suspected aortic injury	3 (0.37)
Hemothorax	1 (0.12)
Sternal fracture	6 (0.75)
Total chest injuries	157 (19.5)
Total abnormal CT C	111 (13.8)

CT C Computed tomography, chest, PE Physical exam
Total number of patients with normal chest PE with CT C = 805

Table 4 Occult chest injuries in negative PE and CXR

Normal chest PE and CXR with abnormal CT C	Number (%)
Bilateral rib fractures	3 (1.1)
Clavicle fracture	1 (0.38)
Lung contusion	7 (2.7)
Pneumothorax	6 (2.3)
1–2 rib fractures	10 (3.8)
3–6 rib fractures	12 (4.6)
> 6 rib fractures	2 (0.77)
Scapular fracture	4 (1.5)
Splenic injury	3 (1.1)
Suspected aortic injury	3 (1.1)
Hemothorax	1 (0.38)
Sternal fracture	5 (1.9)
Total chest injuries	57 (21.8)
Total abnormal CT C	41 (15.7)

CT C Computed tomography, chest, CXR Chest X-ray, PE Physical exam
Total number of patients with normal chest PE and CXR with CT C = 261

Table 5 Occult abdominal/pelvic injuries

Normal abdominal PE with abnormal CT A/P	Number (%)
Bowel wall thickening	2 (0.15)
Free air	2 (0.15)
Liver I-III	21 (1.6)
Liver IV	5 (0.38)
Liver V	2 (0.15)
Mesenteric stranding	6 (0.45)
Pelvic fracture	235 (17.7)
Renal contusion	1 (0.07)
Renal laceration	4 (0.30)
Spleen I-II	18 (1.35)
Spleen III	6 (0.45)
Spleen IV-V	7 (0.52)
Suspicious small bowel injury	2 (0.15)
Total A/P injuries	311 (23.4)
Total abnormal CT A/P	309 (23.2)
Total abdominal injuries excluding pelvis	76 (5.7)

CT A/P Computed tomography of abdomen/pelvis, PE Physical exam
 Total number of patients with normal A/P PE with CT A/P = 1331

were detected in 420 otherwise asymptomatic, evaluable patients. This is 14% of the patients with benign chest exam and 23% with benign abdominal bedside exam findings. One hundred fifty of 592 (25%) patients with a complete benign exam of the torso ended up having occult injuries on CT C/A/P. The known lack of sensitivity of CXR is consistent in our study (61%).

Whether these occult findings are clinically relevant is an important point. Some may argue that clinical importance is only if a procedure is performed or if an early discharge

Table 6 LOS and ISS in asymptomatic body region with negative CT vs no CT

	Negative CT	No CT	Significance
Chest			
n (%)	702 (45)	742 (47)	
LOS	3.45 ± 4.28	4.61 ± 4.14	p < 0.001
ISS	7.35 ± 5.60	6.70 ± 4.73	p = 0.017
A/P			
n (%)	893 (47)	836 (44)	
LOS	3.36 ± 4.07	4.38 ± 3.96	p < 0.001
ISS	8.30 ± 6.57	7.01 ± 4.74	p < 0.001
C/A/P			
n (%)	442 (32)	783 (57)	
LOS	3.29 ± 4.56	4.53 ± 4.11	p < 0.001
ISS	7.83 ± 6.07	6.77 ± 4.61	p < 0.001

A/P Abdomen/pelvis, C/A/P Chest/abdomen/pelvis, CT Computed tomography, ISS Injury Severity Score, LOS Length of Stay
 Values are means ± standard deviations

Table 7 Mortality in asymptomatic body region with and without CT

Body region	Corresponding CT	No corresponding CT	p
Chest	4 (0.3%)	4 (0.3%)	0.575
Abdomen	2 (0.1%)	7 (0.4%)	0.043
Chest/abd/pelvis	2 (0.1%)	4 (0.3%)	0.481

Abd Abdomen, CT Computed tomography

is accomplished. We found the length of stay of a patient receiving negative torso CT was 1 day less than similar patients that did not receive torso CT. Additionally, stratifying patients to level of care (floor versus intensive care unit) has been consistently shown to be important, especially with regard to the number of ribs fractured, even in patients as young as 45 [31, 32]. There is also data that supports significant post-hospital morbidity exists for patients after relatively minor thoracic trauma [33, 34]. Having the knowledge of the full extent of injury may be important in post-discharge rehabilitation plans and expectations.

In addition, quicker diagnosis leads to shorter wait time to intervention when needed. Reporting a negative torso CT is reassuring for both the patient and physician, as well as leading to the shorter hospital length of stay as found in our study.

The limitations of this study include its retrospective nature and lack of cost analysis. The blunt mechanisms were also not stratified based on the height of fall, motor vehicle rollover or ejection, etc. which hinders further and more specific stratification. Various trauma laboratory testing was not recorded as many of the patients were trauma alerts or nonactivations, which often do not have full laboratory testing conducted (i.e., arterial blood gas, urine drug screen). Focused assessment with sonography for trauma (FAST) exams were not consistently performed in this cohort and therefore were not analyzed. FAST exams are generally used in higher acuity patients in shock and performed by trained ER physicians; however, these exams are not used liberally at our institution during this time. Additionally, these were not E-FAST exams and did not include sonography of the chest. Perhaps if these above data points were consistently performed and recorded, a more specific patient population subset could be identified that would better predict the need for cross-sectional imaging of the torso. Finally, there is one concern in this study. The initial indication for CT scanning is variable, as it up to the discretion of the ED physician (based upon physical examination without clear guidelines). This variability means the study must be interpreted with caution, as it is susceptible to bias.

Conclusion

A significant number of occult injuries were detected in stable adult blunt trauma patients with a GCS of 14/15. A negative physical exam combined with a normal CXR

does not rule out the presence of occult injuries and the need for torso imaging. In blunt trauma patients with normal sensorium, physical exam, and CXR, the practice of obtaining cross-sectional imaging would appear to be beneficial by increasing the accuracy of total injury burden and decreasing hospital length of stay. These benefits outweigh the small risk associated with CT scan.

Abbreviations

Abd: Abdomen/abdominal; ATLS: Advanced trauma life support; C/A/P: Chest/abdomen/pelvis; CT: Computed tomography; CW: Chest wall; CXR: Chest X-ray; ED: Emergency Department; FAST: Focused assessment with sonography for trauma; GCS: Glasgow Coma Scale; iCT: Initial computed tomography; INR: International normalized ratio; ISS: Injury Severity Score; MRI: Magnetic resonance imaging; Pan CT: Computed tomography of the head, cervical spine, chest, abdomen, and pelvis; PE: Physical examination; PTX: Pneumothorax; TNICU: Trauma/Neurology Intensive Care Unit

Acknowledgements

Not applicable

Authors' contributions

GJR, LEJ, and JMS contributed to the conception and design of this study. GJR, LC, and JS performed the data acquisition. MA and JC performed the analysis. GJR, LEJ, and JMS performed the interpretation of the result, drafted, and revised the article. AK revised the article and formatted it for submission. GJR, LEJ, and JMS gave the final approval of the submitted version. All authors read and approved the final manuscript.

Funding

This project was self-funded.

Availability of data and materials

The datasets used and/or analyzed during the current study are available from the corresponding author on reasonable request.

Ethics approval and consent to participate

The study was approved by the Institutional Review Board of St. Vincent Hospital.

Consent for publication

Not applicable

Competing interests

The authors declare that they have no competing interests.

Author details

¹Trauma Department, St. Vincent Indianapolis Hospital, 8240 Naab Road #100, Indianapolis, IN 46260, USA. ²Department of Economics, University of the Pacific, Stockton, CA, USA.

Received: 19 September 2019 Accepted: 24 December 2019

Published online: 09 January 2020

References

1. NCIPC: Web-based Injury Statistics Query and Reporting System (WISQARS). Centers for Disease Control and Prevention, Atlanta. 2010. <http://www.cdc.gov/injury/wisqars>. Accessed 26 June 2017.
2. American College of Surgeons. Advanced trauma life support (ATLS): student course manual. 9th ed. Chicago: American College of Surgeons; 2012.
3. Pal JD, Victorino GP. Defining the role of computed tomography in blunt abdominal trauma: use in the hemodynamically stable patient with a depressed level of consciousness. *Arch Surg*. 2002;137(9):1029–32.
4. Richards JR, Derlet RW. Computed tomography and blunt abdominal injury: patient selection based on examination, haematocrit and haematuria. *Injury*. 1997;28(3):181–5.
5. Huber-Wagner S, Lefering R, Qvick LM, Korner M, Kay MV, Pfeifer KJ, et al. Effect of whole-body CT during trauma resuscitation on survival: a retrospective, multicentre study. *Lancet*. 2009;373(9673):1455–61.
6. Poletti PA, Mirvis SE, Shanmuganathan K, Takada T, Killeen KL, Perlmutter D, et al. Blunt abdominal trauma patients: can organ injury be excluded without performing computed tomography? *J Trauma*. 2004;57(5):1072–81.
7. Sampson MA, Colquhoun KB, Hennessy NL. Computed tomography whole body imaging in multi-trauma: 7 years experience. *Clin Radiol*. 2006;61(4):365–9.
8. Salim A, Sangthong B, Martin M, Brown C, Plurad D, Demetriades D. Whole body imaging in blunt multisystem trauma patients without obvious signs of injury: Results of a prospective study. *Arch Surg*. 2006;141(5):468–75.
9. Tillou A, Gupta M, Baraff LJ, Schriger DL, Hoffman JR, Hiatt JR, et al. Is the use of pan-computed tomography for blunt trauma justified? A prospective evaluation. *J Trauma*. 2009;67(4):779–87.
10. Heller MT, Kanal E, Almusa O, Schwarz S, Papachristou M, Shah R, et al. Utility of additional CT examinations driven by completion of a standard trauma imaging protocol in patients transferred for minor trauma. *Emerg Radiol*. 2014;21(4):341–7.
11. Grieshop NA, Jacobson LE, Gomez GA, Thompson CT, Solotkin KC. Selective use of computed tomography and diagnostic peritoneal lavage in blunt abdominal trauma. *J Trauma*. 1995;38(5):727–31.
12. Lavingia KS, Collins JN, Soult MC, Terzian WH, Weirter LJ, Britt LD. Torso computed tomography can be bypassed after thorough trauma bay examination of patients who fall from standing. *Am Surg*. 2015;81(8):798–801.
13. Millo NZ, Plewes C, Rowe BH, Low G. Appropriateness of CT of the chest, abdomen, and pelvis in motorized blunt force trauma patients without signs of significant injury. *AJR Am J Roentgenol*. 2011;197(6):1393–8.
14. Kelleher MS, Gao G, Rolen MF, Bokhari SA. Completion CT of chest, abdomen, and pelvis after acute head and cervical spine trauma: incidence of acute traumatic findings in the setting of low-velocity trauma. *Radiology*. 2016;279(2):395–9.
15. Okamoto K, Norio H, Kaneko N, Sakamoto T, Kaji T, Okada Y. Use of early-phase dynamic spiral computed tomography for the primary screening of multiple trauma. *Am J Emerg Med*. 2002;20(6):528–34.
16. Yeguayan JM, Yap A, Freysz M, Garrique D, Jacquot C, Martin C, et al. Impact of whole-body computed tomography on mortality and surgical management of severe blunt trauma. *Crit Care*. 2012;16(3):R101.
17. Oosthuizen GV, Bruce JL, Bekker W, Shangase N, Laing GL, Clarke DL. Pan computed tomography for blunt polytrauma: are we doing too many? *S Afr Med J*. 2016;106(8):801–3.
18. Van Vugt R, Keus F, Kool D, Deunk J, Edwards M. Selective computed tomography (CT) versus routine thoracoabdominal CT for high-energy blunt-trauma patients. *Cochrane Database Syst Rev*. 2013;12:CD009743.
19. Treskes K, Saltzherr TP, Luitse JS, Beenen LF, Gosliings JC. Indications for total-body computed tomography in blunt trauma patients: a systematic review. *Eur J Trauma Emerg Surg*. 2017;43(1):35–42.
20. Lee WS, Parks NA, Garcia A, Palmer BJ, Liu TH, Victorino GP. Pan computed tomography versus selective computed tomography in stable, young adults after blunt trauma with moderate mechanism: a cost-utility analysis. *J Trauma Acute Care Surg*. 2014;77(4):527–33.
21. Langdorf MI, Medak AJ, Hendej GW, Nishijima DK, Mower WR, Raja AS, et al. Prevalence and clinical import of thoracic injury identified by chest computed tomography but not chest radiography in blunt trauma: multicenter prospective cohort study. *Ann Emerg Med*. 2015;66(6):589–600.
22. James MK, Schubel SD, Francois MP, Doughlin GK, Lee SW. Introduction of a pan-scan protocol for blunt trauma activations: what are the consequences? *Am J Emerg Med*. 2017;35(1):13–9.
23. Ong AW, Castor L, Figueredo R, Butler S, Fernandez F. Pan-body computed tomographic scanning for patients with intracranial hemorrhage after low-energy falls. *Am J Surg*. 2015;209(3):521–5.
24. Caputo ND, Stahmer C, Lim G, Shah K. Whole-body computed tomographic scanning leads to better survival as opposed to selective scanning in trauma patients: A systematic review and meta-analysis. *J Trauma Acute Care Surg*. 2014;77(4):534–9.
25. Self ML, Blake AM, Whitley M, Nadalo L, Dunn E. The benefit of routine thoracic, abdominal, and pelvic computed tomography to evaluate trauma patients with closed head injuries. *Am J Surg*. 2003;186(6):609–13.
26. Sierink JC, Treskes K, Edwards MJ, Beuker BJ, den Hartog D, Hohmann J, et al. Immediate total-body CT scanning versus conventional imaging and selective CT scanning in patients with severe trauma (REACT-2): a randomised controlled trial. *Lancet*. 2016;388(10045):673–83.

27. Sierink JC, Saltzherr TP, Wirtz MR, Streekstra GJ, Beenen LF, Goslings JC. Radiation exposure before and after the introduction of a dedicated total-body CT protocol in multitrauma patients. *Emerg Radiol.* 2013;20(6):507–12.
28. Asha S, Curtis KA, Grant N, Taylor C, Lo S, Smart R, et al. Comparison of radiation exposure of trauma patients from diagnostic radiology procedures before and after the introduction of a panscan protocol. *Emerg Med Australas.* 2012;24(1):43–51.
29. Berrington de Gonzalez A, Mahesh M, Kim KP, Bhargavan M, Lewis R, Mettler F, et al. Projected cancer risks from computed tomographic scans performed in the United States in 2007. *Arch Intern Med.* 2009;169(22):2071–7.
30. Tien HC, Tremblay LN, Rizoli SB, Gelberg J, Spencer F, Caldwell C, et al. Radiation exposure from diagnostic imaging in severely injured trauma patients. *J Trauma.* 2007;62(1):151–6.
31. Murphy CE, Raja AS, Baumann BM, Medak AJ, Langdorf MI, Nishijima DK, et al. Rib fracture diagnosis in the panscan era. *Ann Emerg Med.* 2017;70(6):904–9.
32. Holcomb JB, McMullin NR, Kozar RA, Lygas MH, Moore FA. Morbidity from rib fractures increases after age 45. *J Am Coll Surg.* 2003;196(4):549–55.
33. Daoust R, Emond M, Bergeron E, LeSage N, Camden S, Guimont C, et al. Risk factors of significant pain syndrome 90 days after minor thoracic injury: trajectory analysis. *Acad Emerg Med.* 2013;20(11):1139–45.
34. Emond M, Sirois MJ, Guimont C, Chauny JM, Daoust R, Bergeron E, et al. Functional impact of minor thoracic injury. *Ann Surg.* 2015;262(6):1115–22.

Publisher's Note

Springer Nature remains neutral with regard to jurisdictional claims in published maps and institutional affiliations.

Ready to submit your research? Choose BMC and benefit from:

- fast, convenient online submission
- thorough peer review by experienced researchers in your field
- rapid publication on acceptance
- support for research data, including large and complex data types
- gold Open Access which fosters wider collaboration and increased citations
- maximum visibility for your research: over 100M website views per year

At BMC, research is always in progress.

Learn more biomedcentral.com/submissions

